# Invited review: Camel skin diseases survey in Morocco

**Asma Kamili[1], Bernard Faye[2*], Mohammed Bengoumi[3] and Nour Said Tligui[4]**

[1]Office National de Sécurité Sanitaire des Produits Alimentaires, Rabat (Maroc); [2]U.M.R SELMET, C.I.R.A.D-ES, Montpellier (France); [3]Regional Office F.A.O, Tunis (Tunisie); [4]Institut Agronomique et Vétérinaire (I.A.V) Hassan II, Rabat (Maroc)

## Abstract

The present study aimed to collect data related to skin diseases in dromedary camels in the south of Morocco. As a whole, 168 herds from 9 provinces located in the south of Morocco have been prospected. Finally, 275 camels were involved in this monitoring, presenting 336 skin disease cases with different etiologies (bacterial, viral and parasitic). Mite and dermatophyte infections were predominant with 52% and 30% as respective proportions. On average, 11% and 7% of all cases detected suffered respectively from lymphadenitis and camelpox/ecthyma. Skin diseases in dromedary camels are highly affected by the animal's sex, as females were more affected than males; age seemed to have no effect. The absence of systematic treatment and prevention, even though these infections are all treatable, may somehow explain the recidivism of skin diseases in the herd every year.

**Keywords:** Arabian camel, *Camelus dromedarius*, mange, Morocco, ringworm, skin diseases

*Corresponding author: Dr Bernard Faye, bjfaye50@gmail.com

## Introduction

The Arabian camel (*Camelus dromedarius*) is a rustic animal presenting fewer infectious diseases than cattle, but still vulnerable to skin diseases. Faye et al. (2000) reported that mineral metabolism particularities in camels are distinguished by a remarkable adaptability to mineral under-nutrition and some specificities as increasing of absorption and storage capacity in scarcity periods, tolerance of minerals' excess and maintenance of enzymatic activity in a deficient period. However, a reflection on camel sensitivity to skin diseases suggests that exposure of camels in southern zones in Morocco to prolonged periods of drought may have caused deficiencies in certain minerals which are essential for skin integrity.

Skin diseases are of major concern to farmers in southern Morocco, especially sarcoptic mange, a contagious disease that impact on production, which makes it a redoubted disease among farmers (Khallaayoune et al., 2000; Kumar et al., 1992).

The present study, conducted in the framework of a survey in nine provinces in southern Morocco, aims to collect data on herd management and to make appropriate diagnosis of skin diseases in camels in areas characterized by high camel populations.

The main objectives of the present study were:

- to determine the relative proportions of skin diseases in the camel population in the southern provinces of Morocco,

- to identify risk factors related to the appearance and persistence of skin diseases in camels, and
- to assess the application of medical and preventive measures.

## Material and methods

### *Survey*

The survey was conducted in 9 provinces (Figure 1) located in southern Morocco. Overall, 168 herds of camels were selected randomly and monitored. The number of selected camel herds in each province varied according to the local concentration of camels. The distribution of the herds was 20 in Boujdour, 52 in Dakhla, 10 in Essaouira, 12 in Guelmim, 19 in Laayoune, 14 in Ouarzazate, 12 in Smara, 19 in TanTan and 10 in Tata province.

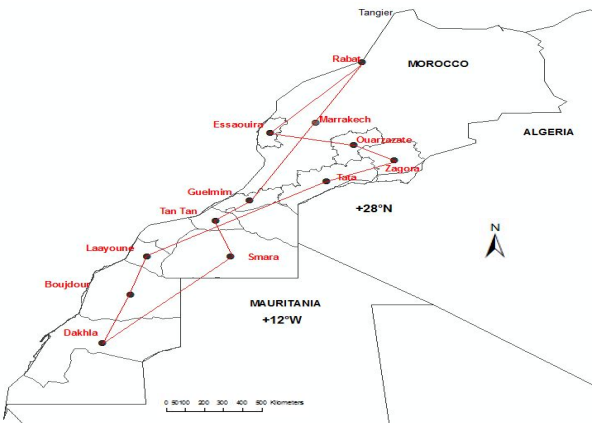


**Figure 1**: Geographical distribution of the Moroccan provinces involved in this skin diseases survey

The survey was based on a questionnaire developed to meet the above objectives. This questionnaire consisted of two sheets:

- Herd form: A sheet was filled in for each herd visited and containing at least one camel with skin lesions. It was used to collect data about owner, herd size and composition, herd management system, herd health history and prophylactic and curative measures implemented by the owner.

- Clinical form: An individual sheet was completed for each animal presenting skin lesions. It was conceived in order to record data related to the animal (age, sex and breed) and to describe detected lesions (camel body location, evolution status, presence of surinfection, lesion progressive stage, extent, contagious nature and period of its appearance) as well as implemented therapeutic and preventive measures. The presence of external parasites such as ticks was also targeted. The presence of external parasites was considered an indicator of the application of prophylactic measures, but those parasites were not collected or diagnosed. The diseases' diagnostic was based on pathognomonic clinical signs and lesions and no further investigations have been conducted to confirm the clinical diagnosis. The negative effect of skin diseases on feeding intake and on milk production was also recorded during the survey, based on interviews with the camel owners and shepherds.

Completed forms were used to conceive a database on Excel. Data entry was followed by database clearing, in order to check the collected information by cross-referencing collected data and photos taken of affected animals. The goal was to get a reliable database and to minimize biases that may be related to errors of registration on the forms or to incorrect answers of the surveyed farmers.

### *Statistical analysis*

The data set was subjected to descriptive and analytical statistical analyses using Excel Software.

To study age and sex effect on the proportion of skin diseases detected in this survey, a Chi-

square test was used when conditions for performing the test were satisfied.

## Results

In the 168 monitored herds, 268 camels were affected with apparent skin lesions corresponding to 336 skin disease cases with variable etiologies: viral, parasitic or bacterial (Table 1). In fact, one animal could present one or more than one skin disease with the following distribution: 103 cases of ringworm, 175 cases of mange, 22 cases of camelpox or camel contagious ecthyma (C.C.E), and 35 cases of lymphadenitis.

Based on pathognomonic clinical signs and lesions, sarcoptic mange was diagnosed in almost half (54%) of the recorded cases and concerned 66% of affected camels; Ringworm was registered in 1/3 of cases with a rate of 30%. Lymphadenitis was detected in 11% of cases and camelpox/C.C.E cases did not exceed 7% (Table 2).

The mean age of studied cases was 6 ± 7 years (74 ± 84 months) with a range of 1–360 months (30 years). Regarding the age distribution, 50% of animals were over 3 years old, 13% between 1 and 3 years old, and 37% under 12 months with a notable difference related to the disease.

Seventy-two percent of mangy animals were over 3 years old, 11% were between one and 3 years old, and 17% were between 1 and 12 months old. For ringworm, the profile was completely different with a higher proportion in young animals: 73% of the cases were recorded in 1 to 12 months old animals, 22% in 1 to 3 years old, and only 5% in animals older than 3 years. Camelpox/C.C.E was diagnosed in 57% of cases in animals less than one year old. Animals between 1 and 3 years old were affected at a rate of 30%, while those over 3 years old were affected in only 13% of cases.

In the current study, confirmatory diagnosis and differential laboratory diagnosis between camelpox and C.C.E was not established. For lymphadenitis, animals under 3 years old were the most affected, with rates of 40% in young ones (under 1 year old) and 43% in 1 to 3 years old camels. Animals older than 3 years affected by this disease presented only 17% of the cases.

Skin diseases in this study were found to be predominant in females (181 camels and 217 cases) with a rate of 69% *versus* 31% in males (85 camels and 105 cases). Nevertheless, this rate varied for each sex according to age. In females, 47% of cases were detected in young camels and 53% in adult animals. For males, it was recorded that 71% of the cases were in young animals and 29% among adults.

Camel skin diseases recorded during this study had a negative effect on feeding intake in about 73% of camels. Nevertheless, this negative effect on feeding intake varied according to the disease. It was about 80% for mange, 61% for ringworm, 91% for camelpox/ecthyma and 63% for lymphadenitis. This effect can be explained either by location of lesions which constitute a physical discomfort for apprehension, chewing or swallowing, or by the presence of pruritus which is a source of discomfort for animals. A negative effect on milk production was also recorded in females with a rate of 35%.

In the present survey, 62% of camels with skin disease were infested by ticks, of which 92% did not receive any antiparasitic treatment as a preventive measure against external parasitic attacks. In addition, dromedary camel herd management in the south of Morocco was characterized by an absence of preventive measures implementation while introducing new animals into the herd. Indeed, no animal quarantine or antiparasitic applications were observed for newly introduced animals. In the case of affection by skin disease, it is not common (never in excess of 15%) to resort to veterinary doctor or livestock technician

**Table 1**: Distribution of camel skin diseases in Moroccan provinces

| Provinces | Camels herds | | | | | | Repartition of skin diseases cases | | | |
|---|---|---|---|---|---|---|---|---|---|---|
| | Number of camels | Mean | S.D | Herds (n) | Affected camels (n) | Cases (n) | Ringworm | Mange | Camel pox | Lymphadenitis |
| Guelmim | 997 | 83 | 52 | 12 | 18 | 19 | 9 | 6 | 2 | 2 |
| Tan Tan | 794 | 42 | 35 | 19 | 38 | 49 | 10 | 28 | 4 | 7 |
| Laayoune | 1576 | 83 | 60 | 19 | 36 | 47 | 14 | 26 | 5 | 2 |
| Boujdour | 1658 | 83 | 41 | 20 | 32 | 40 | 13 | 21 | 1 | 5 |
| Dakhla | 4777 | 92 | 54 | 52 | 88 | 110 | 41 | 52 | 2 | 15 |
| Smara | 918 | 77 | 63 | 12 | 16 | 20 | 7 | 10 | 1 | 2 |
| Tata | 432 | 43 | 29 | 10 | 16 | 26 | 9 | 9 | 6 | 2 |
| Ouarzazate | 239 | 17 | 13 | 14 | 14 | 15 | 0 | 14 | 1 | 0 |
| Essaouira | 35 | 4 | 2 | 10 | 10 | 10 | 0 | 9 | 1 | 0 |
| Total | 11426 | 68 | 54 | 168 | 268 | 336 | 103 | 175 | 23 | 35 |

**Table 2**: Camel skin diseases distribution, effect of age and sex

| Disease | Female | | Male | | Total | Diseases distribution* (%) |
|---|---|---|---|---|---|---|
| | Young | Adult | Young | Adult | | |
| Mange | 36 | 89 | 30 | 20 | 175 | 54<br>66 |
| Ringworm | 57 | 5 | 28 | 2 | 92 | 29<br>35 |
| Lymphadenitis | 11 | 9 | 8 | 4 | 32 | 10<br>12 |
| Camelpox | 10 | 0 | 12 | 1 | 23 | 7<br>9 |
| Total | 114 | 103 | 78 | 27 | 322 | |
| Cases (n) | 217 | | 105 | | 322 | |
| Affected animals (n) | 181 | | 85 | | 266** | |

*: the 1st line represents the proportion related to the total of cases and the 2nd line represents the proportion of the same disease related to total of affected camels; **: Data related to the sex of two animals was not recorded.

competencies; isolation of affected animals from others apparently healthy, as a preventive measure, was observed in only 3% of cases.

Skin disease treatment application in dromedary camels was dependant on the detected diseases. Indeed, for mange and ringworm a medical injection (based on ivermectin (ND), a medicine distributed freely by Moroccan veterinary services to camel owners in this region), or traditional treatment (most of the time cade oil or drain oil) was established in 40% and 63% of cases respectively. Treatment was applied in 35% of camelpox/C.C.E cases and 17% of lymphadenitis cases.

### *Macroscopic description of skin diseases*

Mange was characterised by localized generalized form which presented 36% of detected cases. Lesions mainly affected the neck (51%), legs (35%), abdomen (34%) and/or head (15%). They were characterized by the presence of areas of diffuse alopecia with scabs associated or not with hyperkeratosis. Lesions were pruriginous with a low rate of surinfection (4% of mange cases) (Photos 1).

Ringworm animals showed characteristic lesions with circumscribed areas of alopecia covered by crust. They were mostly located on the abdomen (61%), legs (24%), neck (18%) and/or head (4%). The generalized form was diagnosed in 33% of cases. Lesions of surinfection were rare and hardly exceeded 3% of cases (Photos 2).

For camelpox/C.C.E, lesions were localized in all studied cases and the generalized form was not diagnosed. The most affected areas were mainly the lips (100%), nostrils (57%) and chin (26%). Detected lesions were either vesicles, papules or ulcers with a surinfection rate of 13%. In animals with camelpox/C.C.E, a negative effect on feeding intake was detected in 91% of the cases (Photos 3).

Lymphadenitis was present with two forms, namely skin abscesses in about 54% of cases and ganglionic abscesses in about 43%. The number of animals presenting both forms was limited to a rate which did not exceed 3%. In addition, 63% of dromedary camels with lymphadenitis showed a decrease in feeding

intake and lesions were surinfected in 66% of cases (Photos 4).

Skin abscesses were detected mainly on the head (53%), chest and abdomen (37%) and legs (32%). Ganglionic abscesses mainly affected anterior body parts with a predilection for prescapular (47%) and cervical lymph nodes (40%). Detected cases in the posterior body part mainly concern popliteal (13%) and mammary (13%) lymph nodes (Photos 4).

### *Effect of intrinsic factors on skin diseases proportion (age and sex)*

Sex had no significant effect on the proportions of the four studied skin diseases (mange, ringworm, camelpox/C.C.E and lymphadenitis) at P=0.05 ($\chi^2$ = 7.63 <7.81).

The study of sex effect on the parasitic diseases proportion, mange and ringworm, also showed that there was no effect of sex at P=0.05 ($\chi^2$ = 0.47 <3.84). Neverthless, sex had a highly significant effect on the mange proportion (P<0.001; $\chi^2$ = 14.80> 10.83). Indeed, females were more affected than males.

The effect of sex on the lymphadenitis propotion was not significant at P=0.05 ($\chi^2$ = 0.42 <3.84). The study of sex effect on the relative proportion of the two detected forms of lymphadenitis was also in favor of the absence of a significant effect at P=0.05 ($\chi^2$ = 0.14 <3.84).

The effect of sex on ringworm and camelpox/C.C.E proportions was not studied since the theoretical values of proportions, specific to each of these two diseases, in the contingency table were less than 3.

Age had a highly significant effect (P<0.001) on the proportions of the four studied diseases ($\chi^2$= 88.33 > 16.27).

The effect assessed on the proportion of each separate disease showed that age had a highly significant effect (p<0.001; $\chi^2$ = 14.80> 10.83) on mange and no significant effect at p = 0.05 ($\chi^2$=0.42 <3.84) on the lymphadenitis proportion. A study of age effect on ringworm and camelpox/C.C.E proportions was not performed since the theoretical values of proportions, specific to each of these two diseases, in the contingency table were less than 3.

The relative proportion of skin abscesses and ganglionic abscesses was not affected by age and the effect remained not significant at P= 0.05 ($\chi^2$ = 0.42 <3.84).

**Photos 1**: Mange cases (from left to right: animal scratching, generalized form, neck, rump and head)

**Photos 2**: Ringworm cases (from left to right: abdomen, neck, tail and head)

**Photos 3**: Camelpox and camel contagious ecthyma (CCE) cases

**Photos 4**: Lymphadenitis cases (from left to right: cheek, mandibular interspace and shoulder)

## Discussion

The present study was part of a project aiming to study skin diseases' importance in dromedary camels in Morocco. It was a continuation of a study carried out in slaughterhouses in three provinces in southern Morocco (Guelmim, Tan Tan and Laayoune) in order to draw up epidemiological and histopathological patterns of skin diseases diagnosed in dromedary camels intended for slaughter.

Nevertheless, interpretation of the epidemiological data and their extrapolation on the dromedary camel population in Morocco was limited by study conditions. Camels presented for slaughter are about 67% males and youngs (less than 3 years old) which is not representative of the camel population in Morocco. This is obviously explained by herd management where females are kept for herd renewal and by consumers' preference for meat provided by young dromedary camels (Driot et al*.,* 2011).

The present survey was conducted to provide a closer picture of skin diseases in the dromedary camel herd in the Moroccan regions which are characterized by high concentrations of dromedary camel populations.

### *Mange*

Mange mean prevalence did not exceed 12% among all examined dromedary camels presented to the slaughterhouse (Driot et al., 2011). Nevertheless, the present work showed a proportion slightly higher than peak prevalence, up to 42%, which was found at Laâyoune slaughterhouse, during a study conducted in 1994 (Khallaayoune et al., 2000). Indeed, mange was diagnosed in almost half the cases and about 2/3 of the studied camel populations.

These data are concordant with Bornstein and Younan (2013) who reported that skin diseases due to different aetiologies (arthropods, bacteria, fungi and virus) are often observed in camels. Other than ringworm, camelpox and contagious echtyma (O.R.F), the most common prevalent condition was sarcoptic mange caused by *Sarcoptes scabiei*, which is regarded as one of the most common diseases of camels worldwide (Chaudhary and Akbar, 2000).

In southern Tunisia, Jemli et al. (1995) reported that mange was one of the most common dromedary camel diseases. A similar observation was reported in Morocco (Bengoumi et al., 2005). All dromedary camel farms were infected and about 10% of the animals expressed the disease every year. Camels can be affected by a variety of acarians including *Sarcoptic scabiei, Psoroptes* spp., *Chorioptes* spp. *and Demodex* spp. (Sazmand and Joachim, 2017).

Sarcoptic mange was regarded in a study conducted in Iran as one of the most prevalent diseases of camels and it can also be transmitted to human (Sazmand and Joachim, 2017). In Ethiopia, camels were remarkably exposed to mange caused by sarcoptic acarian with an overall prevalence of 31.5% . *Sarcoptes scabiei* was identified as the only acarian species in all scrappings collected from suspected lesions. This observation is in general agreement with reports by various authors. Even though both sarcoptic and chorioptic mange acarians have been reported, sarcoptic mange caused by *Sarcoptic scabiei* is by far the most common contagious and serious condition in camels (Feyera et al., 2015).

In small camelids of South America, mange was responsible for 95% of losses due to ectoparasites, with a 40% prevalence rate in alpaca and 25% in llama (Twomey et al., 2009). Sarcoptic mange has been described in 4 species of camelids in South America and has been reported in llama and alpaca in the United Kingdom (D'alertio et al*.,* 2005).

According to Legni (1991, cited by D'alertio et

al., 2005), as with other livestock species in terms of prevalence and economic loss, parasitic skin diseases caused by mange were the most important skin diseases affecting camelids in South America.

Mange is easily transmitted in dromedary camel herds due to their skin condition, which is dirty and covered by epidermal debris and secretions, conditions well suited to *Sarcoptes* (Curasson, 1947; Bornstein and Younan, 2013). The infection spreads rapidly within a herd and is responsible for loss in body condition and production. Transmission of mange parasites can be either direct or indirect. The direct is due to camel herds' promiscuity and several other occasions when camels are in contact with each other or when infected camels rub themselves against inanimate objects which surround them. Since these objects are most often rare outside pastures conditions, mangy camels often rub against their congeners. Direct transmission is also frequent from mother to young during suckling periods (Curasson, 1947; Al-Ani and Roberson, 2005; Bornstein and Younan, 2013). It was reported by Feyera et al. (2015) that large herd size and bad body conditions were significantly and positively associated with mange prevalence. Variation in genetics, environment, acessibility to veterinary services, herd size and other husbandry practices can justify reported prevalences of mange in camels. Probably camels living in large herds are more prone to come into contact with infected animals during suckling, herding and housing.

On the other hand, when the infection is initiated, the dromedary camel does not react with pruritus or reacts little and, when it does, the disease is already spread. It has been reported that camel skin is not sensitive enough to withstand attack by insects and reacts less than other animals to contusions and trauma (Curasson, 1947; Bornstein and Younan, 2013). This finding can explain the diffusion and persistence of skin diseases in camel herds, since when first symptoms and lesions appeared, or when animals began to rub against each other or against objects, the infestation was already diffused.

Detected mange clinical signs in this survey are pathognomonic and identical to what has been reported and there was no need to make further investigations to confirm the diagnosis. Indeed, clinical signs are pruritus, hair loss and general condition alteration of the animal. Acute disease can lead to a subacute or chronic form. Mange lesions begin at the neck, inguinal region and thighs. During the acute phase, pruritus is intense which pushes animals to scratch and rub against solid objects, causing depilation and excoriation (Jemli et al., 1995; Schillinger, 1987; Bornstein and Younan, 2013).

Mange lesions were detected in both localized and generalized forms with signs of alopecia and crust with or without hyperkeratosis, depending on the evolution of the disease. Indeed, Bornstein and Younan (2013) reported that commonly recognized mange chronic signs are crusting, thickening (hyperkeratosis), discolouring and fissuring of the skin.

The different mange clinical pictures overall may be related to different stages of disease progression. Beginning mange lesions were only located in thin skin zones, where symptoms usually appear first (head, internal side of legs and axilla), without spread to the rest of the body. The fine crusts and the skin gritty texture may be due to the burst of vesicles where mite begin to burrow into the epidermis. The light-coloured skinned animals exhibited lesions over the same zones as previous animals. However, in this case, the skin was erythematous and there was oedema in body decline parts. These two lesions were typical of mange initial acute phase. In chronic form, lesions were mostly located on the neck, legs and buttock. These are zones frequently in

contact with other camels and easy to scratch. This explains widespread alopecia and skin thickening in reaction to constant itching (Driot et al., 2011; Bornstein and Younan, 2013).

Regarding the ages of affected dromedary camels, in this work 50% of animals with skin diseases were older than 3 years with a variability related to the disease. Indeed, animals older than 3 years were most predisposed to mange. Such results were in concordance with previous studies conducted in camels in other regions over the world. Indeed, mange prevalence is higher in older animals (Faye, 1997; Kumar et al., 1992; Driot et al., 2011).

Females in this study accounted for 69% of the studied camel population. The effect of sex is insignificant in ringworm and lymphadenitis. These data are concordant with Fadlelmula et al. (1994), who reported that mange is a disease observed in growing young animals only, with no difference between the two sexes. Neverthless, the effect of sex was detected in mangy cases. Indeed, females seemed to be more affected than males. Probably, as the adult males used for reproduction are kept in separate pens, the propagation of the disease should be less efficient.

When mange is suspected, diagnosis can be confirmed by demonstration of *S. scabiei* mites in skin scrapings. However, sensitivity of this method is low. The development of an indirect ELISA, demonstrating specific antibodies to *S. scabiei*, for camels is a promising candidate and should be considered as a useful diagnostic and seroepidemiological tool in the future (Bornstein and Younan, 2013).

It is evident in this study that dromedary camel herd managers did not resort frequently to veterinarian or livestock technician competencies for disease diagnosis or treatment. Nevertheless, mange camels are submitted to either traditional or medical treatment.

For many years, ivermectin was provided by the Ministry of Agriculture in Morocco free of charge to breeders in Moroccan southern provinces and disadvantaged regions, to control gastro-intestinal helminthosis, which was responsible for huge economic losses in camels as well as in other species. This medicine also had an effect on ectoparasites like *Sarcoptes*, which may explain the lower prevalence of mange nowadays than in the past (Driot et al., 2011). Frequent and systematic use of ivermectin limited mange spread and reoccurrence in camel herds; the control is based on systematic use of acaricide solutions or ivermectin injections (Jemli et al., 1995). During the study of Twomey et al. (2009), repeated subcutaneous administration of 0.2 mg/kg bodyweight controlled the outbreak successfully. However, the slow response, especially in females, was disappointing, and can be explained by physiological status and hormone changes.

Feyera et al. (2015) reported that drug treatment (ivermectin and diazinon) resulted in a considerable improvement in the clinical score. All treated camels showed a higher degree of recovery with reference to skin texture, healing of skin lesions and disappearance of crusts. The authors concluded that ivermectin had relatively more efficacy than diazinon, as measured by analyses of skin scrapings, body condition and clinical score changes.

### *Ringworm*

The ringworm proportion rose to 16% among all animals, which was slightly lower than what was found in a study carried out from June 2002 to April 2003 in South Morocco, where 26% of the camels were affected (El Jouhari et al., 2004).

Ringworm has an inverse predisposition

compared to mange, i.e., it was detected much more in camels fewer than 3 years old with no registered effect of sex. Indeed, it was published that ringworm prevalence was higher in young calves under one year old (Faye, 1997; Kumar et al, 1992; Driot et al., 2011) and under 3 years of age, and the disease was not observed in animals over 4 years old (McGrane and Higgins, 1985). Other authors concluded that ringworm is a common disease affecting young dromedary camels below three years of age and *T. verrucosum* was the most common dermatophyte affecting camels (Almuzaini et al., 2016; Ganguly et al., 2017).

Classical lesions as described earlier (McGrane and Higgins, 1985; Fadlelmula et al., 1994; Al-Ani and Roberson, 2005), circular and known as "ringworm", were detected in this study mainly in the abdomen, legs and neck with a low rate of surinfection. Clinical examination of affected animals showed squamous and crustal circular lesions with areas of alopecia, but sometimes extensive affected areas were noted (Al-Ani and Roberson, 2005).

The diversity of ringworm clinical presentations is associated with the various stages of the disease evolution. This change depends on the balance between the host and the parasite, which depends on climate, more or less favourable to fungal development, and on applied treatments (El Jouhari et al, 2004).

Several studies showed that climatic factors also intervene directly or indirectly. For example, a mild and humid weather is favourable to fungal growth, and hence to ringworm development. The peak incidence of ringworm was recorded in autumn and winter, while the incidence was lower in summer. Indeed, camel skin and damp hairs during rainy seasons can promote the adhesion of dermatophyte *arthroconidia* and therefore the infection is established more frequently during dry seasons. Rain can help the spread of infected material from skin flaps found on the ground (Curasson, 1947; McGrane and Higgins, 1985; Scott, 1988; Fadlelmula et al., 1994).

This study showed that ringworm lesions were commonly treated, using medical or traditional treatment without veterinary assistance. It was reported that ringworm lesions can expand in size, and signs of emaciation and fatigue appeared in most affected animals. The disease can even cause death of affected animals (Fadlelmula et al., 1994; Al-Ani and Roberson, 2005). In most cases, spontaneous recovery occurred, although some camels remained infected. Infected camels sould be separated and all instruments and harnesses must be disinfected. Antifungal drug therapy has been used to treat camels suffering from fungal infection. Immunization of susceptible camels, by killed or live attenuated fungal vaccines, was recommended (Al-Ani and Roberson, 2005).

Ringworm, although considered rare in camels, is a major public and veterinary health problem. However, the incidence of ringworm is starting to increase in racing camels due to intensive housing. Direct contact with other infected animals and the use of contaminated utensils are common ways in which ringworm can spread. The introduction of new camels with subclinical infection is usually the source of infection to susceptible herds (Al-Ani and Roberson, 2005; Al Tayib, 2019). It was reported in a case study in Saudia Arabia (Sabra and Al Harbi, 2014) that there is a high level of zoophilic dermatophytosis, a sporadic infection of farmers caused by *Dermatophytes* spp. The frequency of zoophilic fungal infections among farmers is higher compared to non-farmers, and there is an occupational relationship since the same fungus was isolated from both the animal and worker (Sabra and Al Harbi, 2014). A recent case of zoonotic dermatophytosis in camels was also recorded in India (Tuteja et al., 2019).

### *Camelpox and camel contagious ecthyma (C.C.E)*

Based on clinical signs, camelpox and C.C.E detected cases were very few. It seems that camels under 3 years old were more predisposed to be affected by these diseases. This remark is confirmed by the fact that Poxvirus spreads quickly among herd young that are 2 to 3 years old (McGrane and Higgins 1985) or 1 to 2 years old (Jemli et al., 1995).

Camelpox and C.C.E lesions are localized, mainly in the lips, nostrils and chin, which confirms previous study results conducted in the dromedary camel population in other countries. Indeed, camelpox is a disease well known by breeders and the need for confirmation by laboratory techniques is rarely manifested (McGrane and Higgins, 1985).

The disease is characterized by papulo-vesicular lesions sitting in the lips and chin skin, which often lead to difficulty in chewing and food apprehension and, as a consequence, diseased camels can lose body condition (McGrane and Higgins, 1985; Jemli et al., 1995; Wernery et al., 2014). A brownish crust develops on lesions that usually heal in 3 weeks. Likewise, an increase in the size of lymphatic nodules has been observed. Mammary glands, genitals, inguinal and perianal regions, thighs and sometimes feet are also affected (McGrane and Higgins, 1985). Clinical manifestations range from inapparent to moderate, less frequent infection to a severe systemic infection and death (Yousif et al., 2010). The disease caused death in a dozen cases in southern Tunisia (Jemli et al., 1995).

Camelpox is a contagious disease, widely distributed among camels in India, Pakistan, Afghanistan, Iran, the former USSR, the Middle East, North and East Africa and worldwide, except in the Australian continent (McGrane and Higgins, 1985; Yousif et al., 2010; Bornstein and Younan, 2013). The disease is enzootic in these countries, and sporadic outbreaks occur with seasonal incidence increasing during the rainy season (Yousif et al., 2010).

Epidemics occur relatively regularly and mainly during rainy seasons; outbreaks during dry seasons appear to be mild and usually of the localized form. Severe secondary infections are common in camelpox, and may be localized to the skin or generalized as septicaemia, eventually leading to death. Morbidity is high and mortality is usually low, but it can reach 28% in generalized forms of the disease and 40–50% in calves (Bornstein and Younan, 2013). Herd outbreaks are often associated with withdrawal stress or poor nutritional status. The majority of cases is of average morbidity, and cured animals appear to have long immunity to reinfection. Occasionally, a severe form of the disease which can be fatal is also encountered (McGrane and Higgins, 1985; Bornstein and Younan, 2013).

In Morocco, the disease is known, but its etiology was confirmed only during an epizootic in southern Morocco in 1984. The epidemiological survey showed that the disease is serious in the area where the infection is recently detected, but cured animals are immunized for a long time (El Harrak, 1991). Similar findings were also reported by other researchers (McGrane and Higgins in 1985; Bornstein and Younan, 2013).

In an attempt to prevent the disease, vaccines have been developed and trialed. There is a vaccine commercialized in Morocco (Jemli et al., 1995) and one called Ducapox® has been used in the UAE since 1994 (Bornstein and Younan, 2013).

Camel contagious ecthyma (C.C.E) has been reported in former-USSR, Mongolia, Kenya, Somalia and Sudan (Azwai et al., 1995; Bornstein and Younan, 2013). Azawi et al. (1995) have reported that C.C.E outbreak

occurred in a shared watering area between sheep, camels and goats, which provided an important opportunity for virus transmission from one species to another. Young animals are particularly susceptible, suffering from lesions that often appear around the mouth and nostrils (Azwai et al., 1995; Ganido-Fariña et al., 2008; Bornstein and Younan, 2013). The incidence of endemic C.C.E is higher than that of camelpox. Morbidity can reach 100% (Bornstein and Younan, 2013).

It has been reported by Ganido-Fariña et al. (2008) that among animals with skin infections, there is no evidence of systemic infection. The virus of C.C.E has been found in crusts and it has been suggested that outbreaks are due to contact with the virus in the environment or to the persistence of the virus in subclinical herds, causing periodic and undetectable skin lesions. This theory, however, has not been rigorously explored (Ganido-Fariña et al., 2008).

Skin diseases are one factor that affect camel performances by decreasing food intake in about 73% of studied cases, with a negative effect on milk production in about 35% of cases. In animals with camelpox/C.C.E, a negative effect on feeding was detected in 91% of cases. It was reported that C.C.E lesions can reduce camels' ability to feed, suckle or graze; primary lesions can also be complicated by bacterial effects, fungi and insect larvae (Ganido-Fariña et al., 2008; Bornstein and Younan, 2013).

### *Lymphadenitis*

Lymphadenitis was present in the two common forms of skin and ganglionic abscesses, affecting mainly young camels under 3 years old, that are more predisposed. Secondary infections were frequent, but they were rarely treated.

Lymphadenitis was reported in many countries. Brown (2004) reported that skin abscesses are common in feral camels in central Australia and pus-filled abscesses are commonly detected during ante-mortem and post-mortem inspection at Australian abattoirs. In Jordan, the disease usually affects camels 1–3 years of age, and the incubation period may extend up to 3 months (Tarazi and Al-Ani, 2016). In the former-USSR, the disease was clinically characterized by purulent inflammation of superficial lymph nodes, particularly those of the neck, prescapular and head regions (Buchnev et al., 1987). In Kenya, abscesses involving the skin and subcutis were frequently seen in camels and extended to the lymph nodes. Head, prescapular and presternal lymph nodes were frequently involved. Puncture wounds, bites and secondary infections following diseases such as camelpox may lead to abscess formation (Juma Ngeiywa, 1992).

In Sudan, abscesses involving the skin and adnexia are frequently seen in camels. The lesions may incorporate the skin and subcutaneous tissue, and commonly the lymph nodes and other organs. The invasion of this structure by pyogenic bacteria may be due to wounds. On the other hand, camel grazing pastures are thorny shrubs and thorny trees and bites of animals or secondary infections following diseases may be responsible for a great deal of skin infection. The presence of abscesses usually leads to emaciation and increases the susceptibility of such animals to secondary infections (Mohammed, 2010).

Wounds and abscesses were the third most common disease problem affecting the surveyed camels, with a peak incidence during the rainy seasons. The abscesses are most frequently located in the lymph nodes of the mandibular region (mandibular, parotid, and lateral retropharyngeal) followed by the superficial cervical, subiliac, popliteal, supermammary and scrotal lymph nodes respectively (Mohammed, 2010).

Lymphadenitis lesions can had a negative effect on camels' feed intake depending on abscess localization. Mohammed (2010) reported that carcass lymph nodes were affected in the following order of decreasing frequency: prescapular, prefemoral, superficial inguinal and popliteal lymph nodes.

### *Common factors*

It appears from this study that skin diseases etiology can include several pathogens. The factors that can be implicated strongly in the persistence of these diseases in camel herds in the south of Morocco are mainly:

- presence of ectoparasites (mainly ticks) and absence of a systematic application of antiparasitic treatment as a preventive measure against external parasites;

- lack of biosecurity measures while introducing new camels to a herd (antiparasitic treatment as a preventive measure and animal quarantine).

- absence of treatment or isolation of affected camels.

- lack of water and inadequate preparation for bathing or spraying, leading to inefficient treatment.

Skin diseases have a negative effect on food intake which can affect negatively the dromedary camel production system (milk and meat production, decrease in performance). The gravity of these effects can be directly linked to localization of the lesion which can constitute a physical discomfort for apprehension, chewing or swallowing, or it could be a source of pruritus which affects animal comfort.

Host-parasite interactions depend on the animal body condition and its capacity to build an efficient immune response. Other factors such as age, feeding and infections are likely to influence host defence mechanisms (vermifugation and vaccination against camelpox). Deficiencies, especially in zinc and copper, may also be considered.

## Conclusions

This study showed that parasitic diseases affecting the skin were highly frequent in camel herds in the south of Morocco. In contrast, bacterial and viral skin diseases were less prevalent. It appeared that age had a significant effect on skin diseases prevalence in camels.

The high proportion of mange and ringworm can be explained, among other factors, by herd management practices characterized by the absence of biosecurity measures and the lack of preventive precautions. Furthermore, the lack of acquired post-infestation immunity can explain the recurrence of these diseases every year in the animals and in the herds. Further studies should be conducted to better understand the functioning of the skin immune system in camels and its responses, especially to mite and dermatophyte infestation (mange and ringworm).

## Acknowledgements

The present study was conducted in the context of the P.R.A.D project no:16867 entitled "Skin diseases and mineral metabolism in camel". We thank the Moroccan central and local veterinary services for their support and assistance with the field activities, without which this work would not have been possible.

## References

Al-Ani, F. and Roberson, J. 2005. Fungal infection of camelids. In: "*Desertication combat and food safety- the added value of camel producers*" (B. Faye and P. Esenov Eds), NATO series, IOS press, Amsterdam, 70-84.

Almuzaini, A. M., Osman, S. A. and Saeed, E. M. A. 2016. An outbreak of dermatophytosis in camels (Camelus dromedarius) at Qassim

Region, Central of Saudi Arabia. *Journal of Applied Animal Research.*, 44(1): 126-129.

Al-Tayib, O. A. 2019. An Overview of the Most Significant Zoonotic Viral Pathogens Transmitted from Animal to Human in Saudi Arabia. *Pathogens*, 8(25): 1-32.

Azwai, S.M., Carter, S.D. and Woldehiwet, Z. 1995. Immune response of the camel (camelus dromedarius) to contagiuos ecthyma (O.R.F) virus infection. *Veterinary microbiology*, 47 : 119-131.

Bengoumi, M., Berrada, J. and Faye, B. 2005. La santé du dromadaire : une contrainte majeure de l'élevage camelin dans les zones arides. *Animalis*, 4(1): 5-10.

Bornstein, S. and Younan, M. 2013. Significant veterinary research on the dromedary camels of Kenya: Past and Present. *Journal of Camelid Science* , 6: 1-48.

Brown, A., 2004. Skin and Internal Abscesses. A Review of Camel Diseases in Central Australia. Industry and Resource Development Arid Zone Research Institute. *Alice Springs, NT Agdex 465/650, 1-19*.

Buchnev, K.N., Tulepbaev, S.Z. and Sansyzbaev, A.R. 1987. Infectious diseases of camels in the USSR. *Revue Scientifique et Technique de l'Office International des Epizooties*, 6 (2): 487-495.

Chaudhary, Z.I. and Akbar, S.J. 2000. The camel and its diseases. *Al-Bayan press* (Publ.), Dubai (UAE): 239.

Curasson, G. 1947. *Le chameau et ses maladies*. Edition n° 140. Peau et tissu conjonctif 367.

D'alertio, G.L., Cillaghan, C., Just, C., Manner-Smith, A., Foster, A.P. and Knowles, T.G. 2005. Prevalence of chorioptes sp. mite infestation in alapaca (lama pacos) in the south west of England. Implications for skin health. *Small ruminant research*. 57, 221-228.

Driot, C., Kamili, A., Bengoumi, M., Faye, B., Delverdier, M. and Tligui, N. 2011. Study on the epidemiology and histopathology of sarcoptic mange and ringworm in the one-humped camel in south of Morocco. *Journal of Camel Practice and Research*, 18(1): 1-8.

El Harrak, M., Loutfi, C. and Berlin, F. 1991. Isolement et identification du virus de la variole du dromadaire au Maroc. *Annales de recherches vétérinaires*. 22 : 95-98.

El Jouhari, S., Ouhelli, H. and Yassine, M. 2004. À propos de cas de teignes du dromadaire au Maroc. *Journal de mycologie médicale*, 14(2): 83-87.

Fadlemula, A., Agab, H., Le Horgne, J.M., Abbas, B. and Abdalla, A.E. 1994. First isolation of trichytom verrucosum as the aetiology of ringworm in the Sudanese camels (Camelus dromedarius). *Revue d'Elevage et de Médicine Vétérinaire des Pays Tropicaux*, 47: 184–87.

Faye B., 1997. *Le guide de l'élevage du dromadaire*, 127.

Feyera, T., Admasu, P., Abdilahi, Z. and Mummed, B. 2015. Epidemiological and therapeutic studies of camel mange in Fafan zone, Eastern Ethiopia. *Parasites and Vectors*, 8(612): 1-6.

Ganido-Fariña, G.I., Corneji-cortes, M.A., Martnez-Rodriguez, A., Reyes-Esparza, J., Alba-Hurtado, F. and Tortora Perez, J. 2008. A study of process of apoptosis in animals infected with contagious ecthyma virus. *Veterinary microbiology,* 129:, 28-39.

Ganguly S., Para, P.A. and Praveen, P.K. 2017. Dermatophyte Examination of Skin Scrapings Collected from a Camel: A Case Study. *International Journal of Current Microbiology and Applied Sciences*, 6(2): 1731-1734.

Jemli, M., Zrelli, M., Aridhi, M. and M'zah, M. 1995. Contraintes pathologiques majeures du développement de l'élevage du dromadaire en

Tunisie.. Elevage et alimentation du dromadaire. *Options Méditerranéennes: Série B. Etudes et Recherches,* 13: 131-136.

Juma Ngeiywa, K. J. Z.,1992. Clinical and pathological investigations on camel skin diseases in some camel rich districts of northern Kenyan. *Thesis*, Department of Clinical Studies, Faculty of Veterinary Medicine, College of Agriculture and Veterinary Sciences, University of Nairobi.

Khallaayoune, K., Dakkak, A., Jebri, A., Malik, J., Hidane, K. and Dorchies, P. 2000. Variations saisonnières des infestations par Sarcoptes scabiei var. cameli chez le dromadaire dans le Sud marocain. In: Dakkak A. *Maladies parasitaires et infectieuses du dromadaire*. Rabat, Actes Editions. 42-46.

Kumar, D., Raisinghani, P. M. and Manohar, G. S. 1992. Sarcoptic mange in camels: *a review. In: Proceedings of the First International Camel Conference*. Dubai, United Arab Emirates, 2nd-6th 79-82.

McGrane, A. J. and Higgins, A. J. 1985. Infectious diseases of the camel: viruses, bacteria and fungi. *British Veterinary Journal,* 141(5): 529-547.

Mohammed, A., 2010. Camel Abscesses in the Red Sea State of the Sudan. *Thesis*, Department of Microbiology, Faculty of Veterinary Medicine, University of Khartoum.

Sabra, S. M. M. and Al Harbi, M. S. A. 2014. Search Project Report; Field Study on Farm Workers Occupational Health Hazards Associated with Camels Zoonotic Dermatophytosis, with Reference to Fungal Etiology, and Morbidity Rates, Taif, KSA. *Journal of Agriculture and Veterinary Science*, 7(9): 19-28.

Sazmand, A. and Joachim, A. 2017. Parasitic diseases of camels in Iran (1931–2017) – a literature review. *Parasite*, 24 (21): 1-15.

Schillinger, D. 1987. Mange in camels - an important zoonosis. Revue Scientifique et Technique de l'Office International des Epizooties, 6(2): 479-480.

Scott, D. W. 1988. Fungal Diseases. In: *Large Animal Dermatology, Philadelphia, WB Saunders Company*, 168-202.

Tarazi, Y. H. and Al-Ani, F. K. 2016. An outbreak of dermatophilosis and caseous lymphadenitis mixed infection in camels (Camelus dromedaries) in Jordan. *The Journal of Infection in Developing Countries*, 10 (5): 506-511.

Tuteja, F. C., Jain, G. K., Singh, A. P., Narnaware, S. D., Sawal, R. K. and Patil, N. V. 2019. A zoonotic case of camel dermatophytosis caused by Trichophyton violaceum. *Journal of Camel Practice and Research*, 26(1): 87-90.

Twomey, D. F., Birch, E. S. and Shock, A. 2009. Outbreaks of sarcoptic mange in alpacas (vicugna pacos) and control with repeated subcutaneous ivermectin injection. *Veterinary parasitology*, 159 (2): 186-191.

Wernery, U., Kinne, J. and Schuster, R. K. 2014. Camelid infectious disorders. *World Animal Health Organization (OIE) Bulletin*, 231-240.

Yousif, A. A., Al-Naeem, A. A. and Al-Ali, M. A. 2010. Rapid non enzymatic extraction method for isolating PCR-quality *camelpox virus* DNA from skin. *Journal of virological methods*. 169: 138-142.