

# *Haematoxenus separatus* sp. n. (Sporozoa, Theileriidae), a new blood parasite of domestic sheep in Tanzania

by G. UILENBERG (\*) and M. P. ANDREASEN (\*\*)

## RESUME

*Haematoxenus separatus* sp.n. (Sporozoa, Theileriidae),  
nouvel hématozoaire du mouton domestique en Tanzanie,  
transmissible par tiques

Après une revue du genre *Haematoxenus*, connu chez le bovin, le buffle africain et des antilopes africaines, les auteurs rapportent la découverte d'une nouvelle espèce de ce genre chez le mouton domestique en Tanzanie, *H. separatus* sp. n. Le parasite, apparu chez un mouton après splénectomie, a pu être transmis à un second mouton par inoculation de sang infecté. Le parasite diffère morphologiquement des *Theileriidae* déjà connues chez le mouton par la présence d'un voile, particularité du genre *Haematoxenus*; de plus, ses dimensions sont plus grandes que celles de *Theileria ovis* de Madagascar et de la République Centrafricaine. On ne sait pas encore si des éléments sans voile, apparus en même temps que les formes à voile, appartiennent à l'espèce *H. separatus* ou s'ils doivent être attribués à une infection mixte. Le voile est séparé du parasite, contrairement à celui d'*H. veliferus*. Le voile semble provenir du cytoplasme de l'érythrocyte infesté. La division d'*H. separatus* dans les globules rouges se fait en quatre, comme chez les autres *Theileriidae*. Des stades exo-érythrocytaires n'ont pas encore été observés. Une modification de la définition du genre *Haematoxenus* est proposée.

## INTRODUCTION

The genus *Haematoxenus* was created for an intracellular blood parasite of cattle in Madagascar, *H. veliferus* Uilenberg, 1964. The only stages in the life cycle of this parasite which have been recognized until now are the erythrocytic forms, morphologically similar to

*Theileriae*, apart from the fact that many have a rectangular « veil » arising from the side of the organism. Division in four is also similar to the *Theileriae* (11).

*H. veliferus* has been found in cattle (both *Bos indicus* and *B. taurus*) in Madagascar (10, 11, 12, 13), in Nigeria (4, 3), in Kenya (2, 17), in Uganda (2, 8, 9), in the Central African Republic, the Chad and Mali (14). We have also seen it in a bloodsmear from a cow taken in the Ivory Coast in 1972 by our colleague Dr M. Clair, and recently in several cattle in Tanzania. The parasite is therefore widely spread in tropical Africa, and is quite common

(\*) Tanzania F.A.O./U.N.D.P. Project "Improvement of Tick Control", c/o Central Veterinary Laboratory, P.O. Box 9254, Dar-es-Salaam, Tanzania.

(\*\*) The Royal Veterinary and Agricultural University, Department of Veterinary Virology and Immunology, 13 Bülowsvej, 1870 Copenhagen V, Denmark.

in Madagascar (11, 12, 13), in Uganda (9, UILENBERG and ROBSON, unpublished observations, 1973), in Mali (15) and in Tanzania (UILENBERG, unpublished observations, 1973, 1974).

A morphologically identical parasite occurs in wild African buffaloes (*Syncerus caffer*) in the Central African Republic (14) and in Uganda (17).

*Haematoxenus* also occurs in African antelopes from impala (*Aepyceros melampus*) in Tanzania (5), and YOUNG (personal communication, 1973), has found it in hartebeest (*Alcelaphus buselaphus*) in Kenya. The morphology of the veil of the parasites in antelopes seems to be somewhat different from that of *H. veliferus*, being less regularly rectangular.

In this paper, we describe a new pathogenic parasite of domestic sheep in Tanzania, for which we propose the name *Haematoxenus separatus* sp. n., the "separated" *Haematoxenus*.

## MATERIAL AND METHOD

A lamb (n° 1549) of the local breed of sheep, approximately 6 months old, born at Dar-es-Salaam, was splenectomized. Scanty theilerial parasites had been seen on one occasion in its blood prior to the operation, and it was hoped to obtain a high parasitaemia of *Theileria ovis* Rodhain, 1916, for transmission experiments with ticks. A second lamb, black-headed Persian, approximately one month of age, born at Dar-es-Salaam, was also splenectomized; it was hoped that this young animal, born in a flock where some tick control was practised, would still be free from *T. ovis*, in order to serve for transmission experiments.

## OBSERVATIONS ON THE SHEEP

### Lamb n° 1549

Scanty theilerial organisms appeared in its blood 3 days after splenectomy. They increased in number from day 6 after the operation, until on day 17 over 5 p. 100 of the erythrocytes were infested; the parasitaemia decreased after this maximum and the parasites were again scanty on day 21.

Theilerial organisms associated with veils were first noted on day 6. Their number increased at the same time as that of the normal theilerial organisms, until on day 17 a maximum of at least 1 p. 100 of erythrocytes infested was reached; their decrease also paralleled that of the normal organisms. During this period, the proportion of organisms associated with a veil to the normal ones appeared to remain relatively stable, at any one time some 10 to 15 p. 100 of the total number of parasites being associated with a veil. Both types fluctuated in number after day 21, from very scanty to fairly numerous (never exceeding 0,2 p. 100 of cells infested), and both could be found for at least fourteen months after splenectomy. The ratio of veiled to unveiled parasites appeared far less constant during this period of low parasitaemia.

Lamb 1549 also showed *Anaplasma ovis* Lestoquard, 1924 after the operation. The first anaplasms appeared on day 10, and they had become so numerous, associated with marked anaemic changes in the blood picture, on day 20, that the animal was treated with a tetracycline (Reverin®) at 10 mg/kg. The anaplasms then disappeared within a few days and have not been seen again.

Fever was noted on days 11 to 13, with a maximum of 41,0° C on day 12, associated with a rapid rise in number of both types of theilerial organisms, while *A. ovis* was still scanty. Anaemia was noted from day 19 onward, while the theilerial parasites were decreasing in number, associated with a rapid increase in parasitaemia by *A. ovis*; anaemic changes in the blood picture were most pronounced on days 21 to 23.

### Persian lamb

No blood parasites appeared following splenectomy. On day 40 after the operation, it was injected subcutaneously with 5 ml of blood taken from lamb 1549. This was 58 days after the splenectomy of lamb 1549; both types of theilerial parasites were fairly numerous in its blood that day.

Very scanty theilerial organisms were seen in the blood of the Persian lamb 18 days after this injection. The type associated with a veil was observed with certainty 21 days after the injection. Unfortunately, the animal, which had

lost its mother and had become very weak, died 22 days after the injection.

## DESCRIPTION OF *HAEMATOXENUS SEPARATUS* SP. N.

### Morphology

(methanol fixation, Giemsa staining)  
(fig. 1, 2, 3, microphoto)

*Theileria*-like organisms in the red blood cells, associated with a veil that does not arise from the parasite as in *H. veliferus*, but is separated from it. The long axis of the veil does not seem to have any particular orientation in relation to the parasite. No difference in colour or intensity of staining between the veil and the cytoplasm of the red cell has been observed, except in erythrocytes in the process of lysis, when the veil retains its original colour, while the normal cell cytoplasm becomes faint. The veil is most commonly situated outside the red cell, opposite a corresponding gap in the cell, and it appears to originate from erythrocyte cytoplasm. The veil can also be situated on or in the cell, in which case it is surrounded by an unstained halo. [A similar gap around the veil of *H. veliferus* is commonly seen, see UILENBERG (13, p. 432)]. The organism and its associated veil are sometimes seen lying free between the red cells, presumably a result of lysis of the host cell. The shape of the veil is on the whole rectangular, but the angles are commonly rounded, and ellipsoid and crescent-shaped veils occur. The dimensions of the veils vary from slightly more than 1  $\mu$  to over 3  $\mu$  in length, with a width of approximately 0,5  $\mu$  to more than 1  $\mu$ .

The organisms are typically *Theileria*-like. Round and oval parasites predominate, narrow rod-shaped ones also occur, but are less frequent. The largest parasites are well over 2  $\mu$  in length, the smallest are approximately 1,5  $\mu$ .

Dividing forms, associated with a veil, are present. Division is as in *Theileria*, with the formation of a Maltese cross, resulting in four small parasites.

Some or all of the unveiled theilerial organisms present at the same time as typical *H. separatus*, may belong to this species; small theilerial organisms without veils also occur in *H. veliferus* (11). Their average dimensions

are less than those of typical *H. separatus*; many are only 1  $\mu$  by less than 0,5  $\mu$ .

### Life cycle

Unknown, apart from multiplication in four in the red cells.

### Host

Domestic sheep.

### Transmission

Artificial transmission is possible by subcutaneous injection of infected blood.

### Pathogenicity

The fever in lamb 1549, although the temperature was normal at the maximum of the theilerial parasitaemia, may have been caused by the (possibly mixed) theilerial parasites, as *A. ovis* was still scanty at that time. The anaemia in lamb 1549 may well have been due mainly to *A. ovis*.

### Differential diagnosis

*H. separatus* differs from *T. ovis* and *Theileria hirci* Dschunkowsky and Urodschewich, 1924 in the presence of the veil. The veil is such a striking feature that it is inconceivable that the different authors who have observed sheep *Theileriae* could have overlooked it. *T. hirci* has only been reported from northern Africa, southern Europe and Asia Minor, while *T. ovis*, the only other known *Theileria* of sheep, has been reported from many parts of Africa, including Tanzania [see for instance NEITZ (7)]. We have compared *H. separatus* to what we consider to be *T. ovis* from splenectomized sheep in Madagascar and the Central African Republic. The biggest forms of *T. ovis* do not reach the size of some almost *Babesia*-like parasites of well over 2  $\mu$  that are found in *H. separatus*. No veils like those of *H. separatus* were seen in smears from Malagasy and Central African sheep. Within some of the *T. ovis* infested red cells a darker patch like an ill-defined veil was seen, as well in smears from Madagascar as from the Central African Republic; this has been reported before in Malagasy sheep (13). Such darker patches, which are quite different from the clearly defined veils of *H. separatus* or *H. veliferus*,

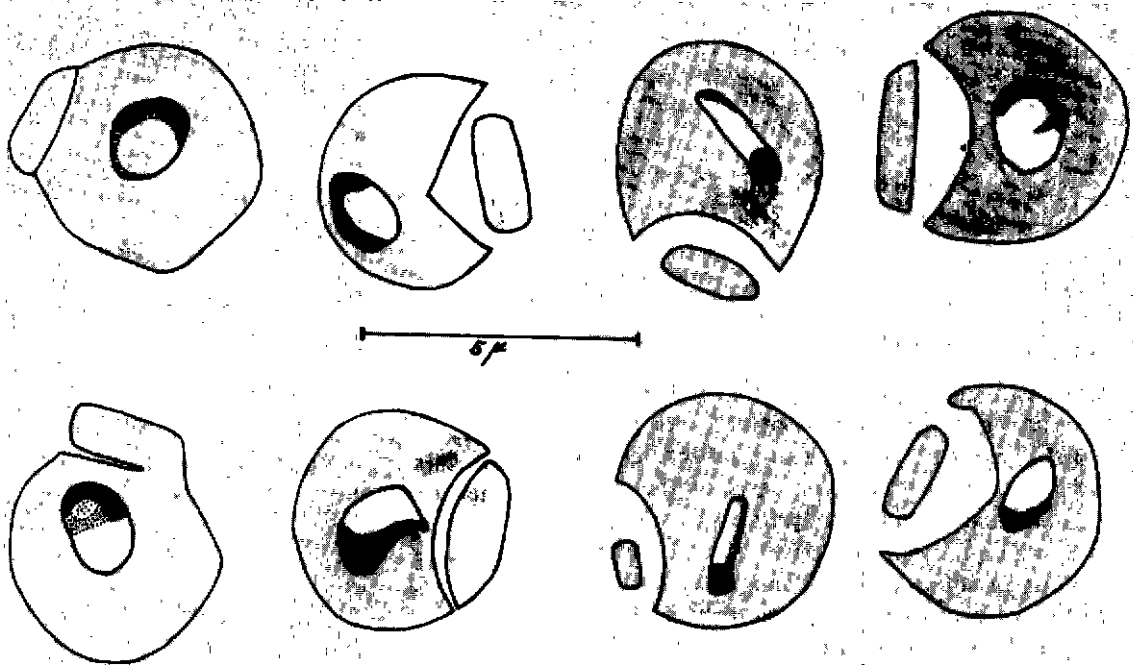


Fig. 1. — *Haematoxenus separatus* dans les erythrocytes de mouton.

Fig. 1. — *Haematoxenus separatus* in sheep erythrocytes.

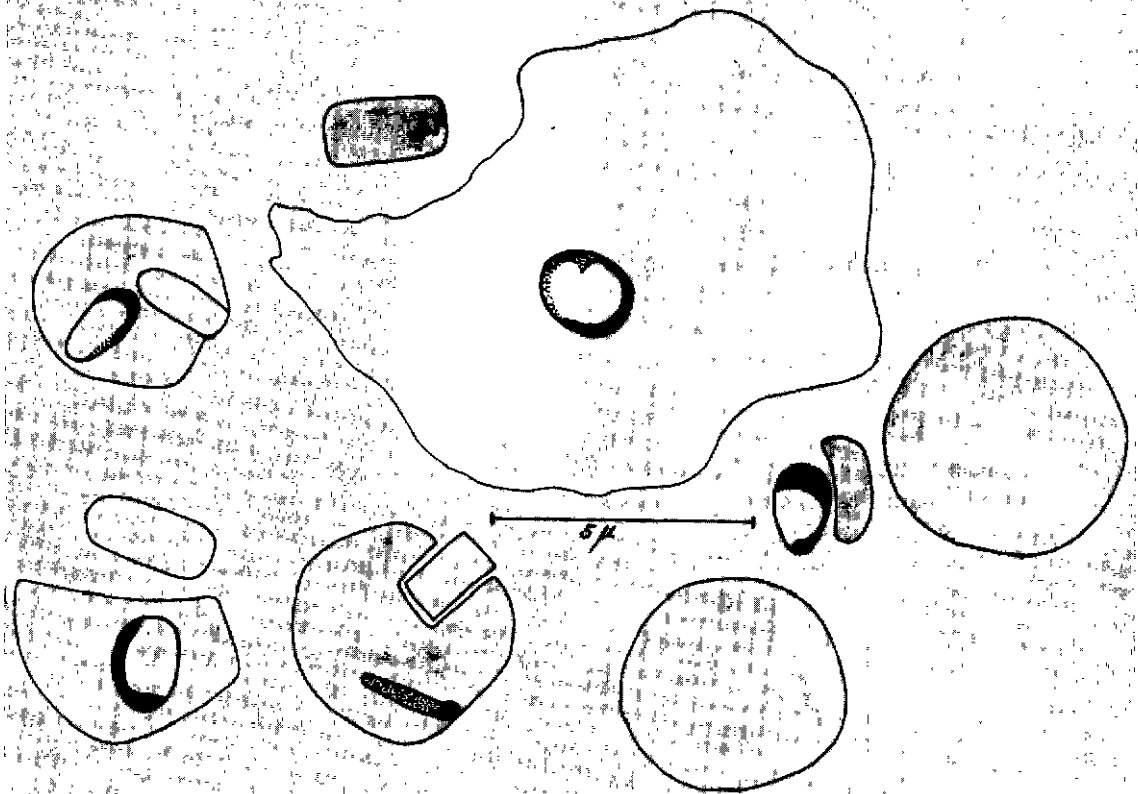


Fig. 2. — *Haematoxenus separatus* comprenant un parasite libre avec voile et un parasite dans un globule rouge en voie de lyse, le voile gardant sa couleur originale.

Fig. 2. — *Haematoxenus separatus*, including one free-lying parasite with veil, and one parasite in lysing red cell, the veil retaining its original colour.

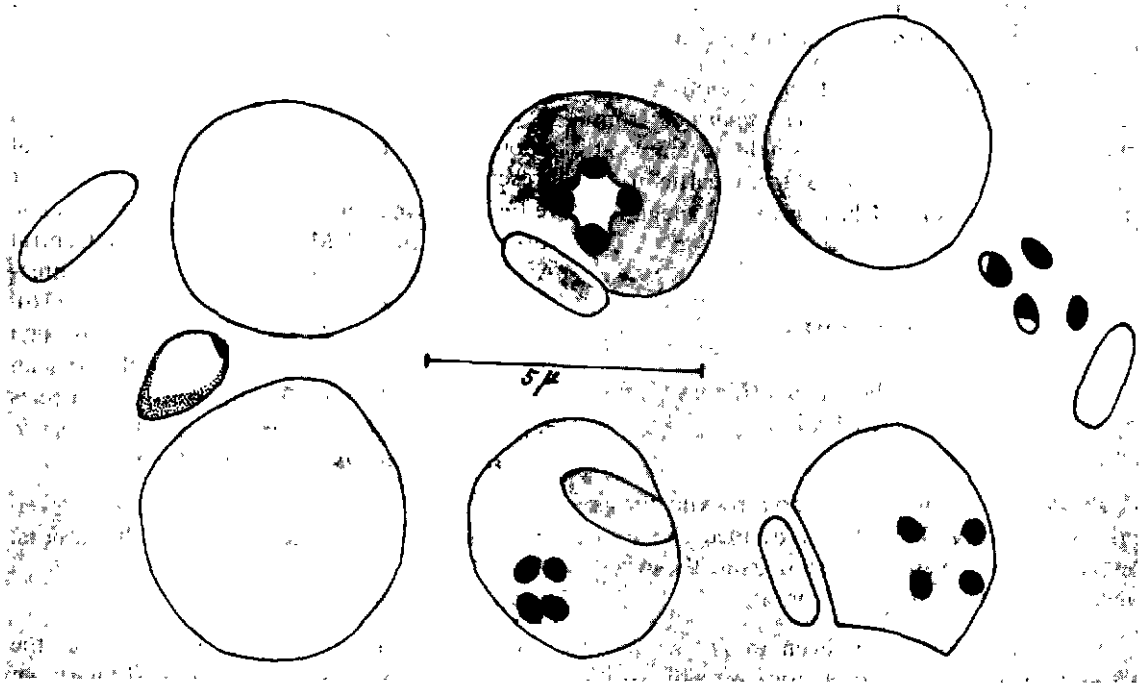


Fig. 3. — *Haematoxenus separatus* comprenant un parasite libre avec voile, trois formes en division dans des globules rouges, et un parasite libre qui vient apparemment de terminer sa division en 4, avec son voile.

Fig. 3. — *Haematoxenus separatus*, including one free-lying parasite with veil, three dividing forms in red cells, and one free-lying parasite that has apparently just completed its division in four, with accompanying veil.

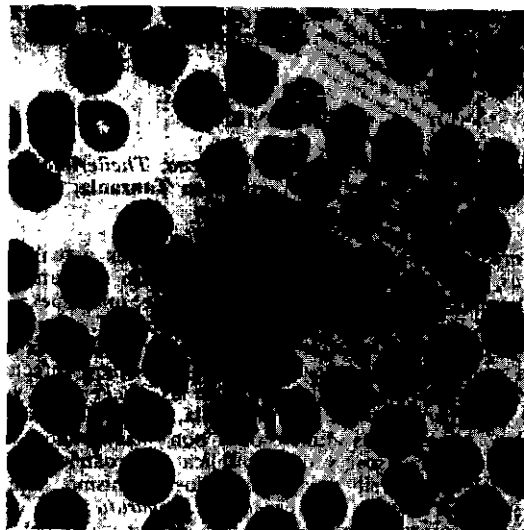


Fig. 4. — Microphotographie d'*Haematoxenus separatus* dans les erythrocytes de mouton.

Fig. 4. — Microphotograph of *Haematoxenus separatus* in sheep erythrocyte.

have not been seen in red cells of lamb 1549 infested with unveiled or veiled organisms.

The position of the veil in relation to the parasite is quite different in *H. separatus* from that in *H. veliferus*. One single attempt at transmission of *H. veliferus* from cattle to a splenectomized sheep has given a negative result (11).

## DISCUSSION

The definition of the genus *Haematoxenus* by BARNETT (1) and LEVINE (6) should be amended as follows :

*Theileriidae* in which the erythrocytic forms are associated with a clearly defined more or less rectangular veil, separated from the organism or appearing to arise from it.

As noted before (15), even in *H. veliferus* the veil probably does not arise directly from the organism, but seems to be separated from it by a narrow band of erythrocytic cytoplasm, visible with the electron microscope (unpublished electron microscopic photographs made by Dr H. M. D. HOYTE, Brisbane, 1965). It

now appears that the veil originates from erythrocytic cytoplasm. Its mode of origin and its function remain quite unknown.

Veil-like structures may be more wide-spread amongst the *Theileriidae* than is realized at present. As noted above, darker patches of red cell cytoplasm are associated with some forms of *T. ovis* in Madagascar and the Central African Republic. They also occur in infections with the British cattle *Theileria* (16), which may not be *T. mutans* after all, as such structures have not been seen with African or Malagasy *T. mutans*. Intermediate species between typical representatives of *Theileria* and *Haematoxenus* might thus occur.

Specimen slides of *H. separatus* have been deposited in the collections of both authors.

## Acknowledgements

We are grateful to the Director of the Livestock Development of the Ministry of Agriculture and to the Director of the Central Veterinary Laboratory in Dar-es-Salaam for permission to publish this paper. We also wish to thank Mr D. S. M. Kadaso, Assistant Field Officer, for his assistance.

## SUMMARY

The authors describe a new species of the *Theileriidae*, *Haematoxenus separatus* sp. n., in domestic sheep in Tanzania. The parasite appeared in the blood after splenectomy of a carrier, transmission by injection of infected blood was successful. The veil of this species is separated from the parasite, not appearing to arise from it as in *H. veliferus* of cattle. An amendment for the definition of the genus *Haematoxenus* is proposed.

## RESUMEN

*Haematoxenus separatus* sp. n. (*Sporozoa*, *Theileriidae*) nuevo hematozoario de la oveja doméstica en Tanzania, trasmisible por garrapatas

Los autores pasan en revista los conocimientos actuales del genero *Haematoxenus*, conocido en el bovino, el búfalo africano y antílopes africanos. Después, notan el descubrimiento de una nueva especie de dicho genero en la oveja doméstica en Tanzania, *H. separatus* sp. n. Se pudo transmitir el parásito, encontrado en una oveja después de esplenectomía, a una segunda oveja por inoculación de sangre infectada.

El parásito difiere morfológicamente de las *Theileriidae* ya conocidas en la oveja por la presencia de una vela, particularidad del genero *Haematoxenus*. Además sus dimensiones son más grandes que las de *Theileria ovis* de Madagascar y de República Centroafricana. No se sabe todavía si los elementos sin vela, aparecidos al mismo tiempo que las formas con vela, pertenecen a la especie *H. separatus* o si deben de ser atribuidos a una infección mixta. La vela es separada del parásito, al contrario de la de *H. veliferus*. Parece provenir del citoplasma del eritrocito infestado. *H. separatus*, como los otros *Theileriidae*, se divide en cuatro en los glóbulos rojos. No se observaron todavía estados exo-eritrocitarios. Se propone una modificación de la definición del genero *Haematoxenus*.

## LITERATURE REFERENCES

1. BARNETT (S. F.). Theileriasis. In : WEINMAN (D.) and RISTIC (M.). Infectious blood diseases of man and animals. Diseases caused by Protista. Vol. II. The pathogens, the infections, and the consequences. New York and London, Academic Press, 1968 : 269-328.
2. BUYS (J.), FOLKERS (C.) and PERIE (N. M.). *Haematoxenus veliferus* in cattle in Uganda and Kenya. *J. Parasit.*, 1969, **55** : 1066.
3. FOLKERS (C.), BUYS (J.), BLOTKAMP (J.), VAN HOEVE (K.) and KUIL (H.). Survey on blood parasites of cattle presented for treatment against trypanosomiasis in Nigeria. *Bull. epiz. Dis. Afr.*, 1970, **18** : 215-220.
4. FOLKERS (C.) and KUIL (H.). Blood-parasites in cattle, sheep and goats in Northern Nigeria. *Bull. epiz. Dis. Afr.*, 1967, **15** : 121-123.
5. IRVIN (A. D.), OMWOYO (P.), PURNELL (R. E.), PEIRCE (M. A.) and SCHIEMANN (B.). Blood parasites of the impala (*Aepyceros melampus*) in the Serengeti National Park. *Vet. Rec.*, 1973, **93** : 200-203.
6. LEVINE (N. D.). Taxonomy of the piroplasms. *Trans. Am. Microsc. Soc.*, 1971, **90** : 2-33.
7. NEITZ (W. O.). Theilerioses. In : BRANDLY (C. A.) and JUNGHER (E. L.). *Adv. Vet. Sci.*, Vol. V., New York and London, Academic Press, 1959 : 241-297.
8. OTENG (A. K.). *Haematoxenus veliferus* Uilenberg, 1964 : a new piroplasm of cattle, recorded at Entebbe, Uganda. *Bull. epiz. Dis. Afr.*, 1970, **18** : 19-20.
9. OTENG (A. K.) and ODEKE (G. M.). The incidence of *Haematoxenus veliferus* (Uilenberg, 1964) in cattle in Serere and Kyoga Counties of Uganda. *East Afr. Agric. For. J.*, 1972, **37** : 211.
10. UILENBERG (G.). *Haematoxenus veliferus*, n.g., n. sp., parasite *incertae sedis* du sang de bovins à Madagascar. *Rev. Elev. Méd. vét. Pays trop.*, 1964, **17** : 655-662.
11. UILENBERG (G.). Acquisitions nouvelles dans la connaissance d'*Haematoxenus veliferus* hématozoaire des bovins à Madagascar. *Bull. Soc. Path. exot.*, 1965a, **58** : 432-445.
12. UILENBERG (G.). Influence du détiqage sur la présence de parasites sanguins chez les bovins malgaches observés après splénectomie. Indications pratiques pour la lutte contre les hématozoaires pathogènes. *Rev. Elev. Méd. vét. Pays trop.*, 1965b, **18** : 165-173.
13. UILENBERG (G.). *Haematoxenus veliferus*, hématozoaire des bovins à Madagascar. Note complémentaire. *Rev. Elev. Méd. vét. Pays. trop.*, 1965c, **18** : 429-433.
14. UILENBERG (G.). Existence d'*Haematoxenus veliferus* (Sporozoa, Theileriidae) en Afrique Centrale. Présence d'*Haematoxenus* sp. chez le buffle africain. *Rev. Elev. Méd. vét. Pays. trop.*, 1970, **23** : 455-456.
15. UILENBERG (G.). Contribution à la connaissance des protozoaires et Rickettsiales sanguicoles et des tiques d'animaux à Madagascar. Ph. D. Thesis, State University, Utrecht, 1972 : 12.
16. UILENBERG (G.), ROBSON (J.) and PEDERSEN (V.). Some experiments on the transmission of *Theileria mutans* (Theiler, 1906) and *Theileria parva* (Theiler, 1904) by the ticks *Amblyomma variegatum* (Fabricius, 1794) and *Rhipicephalus appendiculatus* Neumann, 1901, in Uganda. *Z. Tropenmed. Parasit.*, 1974, **25** : 207-216.
17. YOUNG (A. S.), IRVIN (A. D.) and WOODFORD (M. J.). *Haematoxenus* species from Ugandan buffalo *Syncerus caffer*. *J. Wildlife Dis.*, 1973, **9** : 94-98.